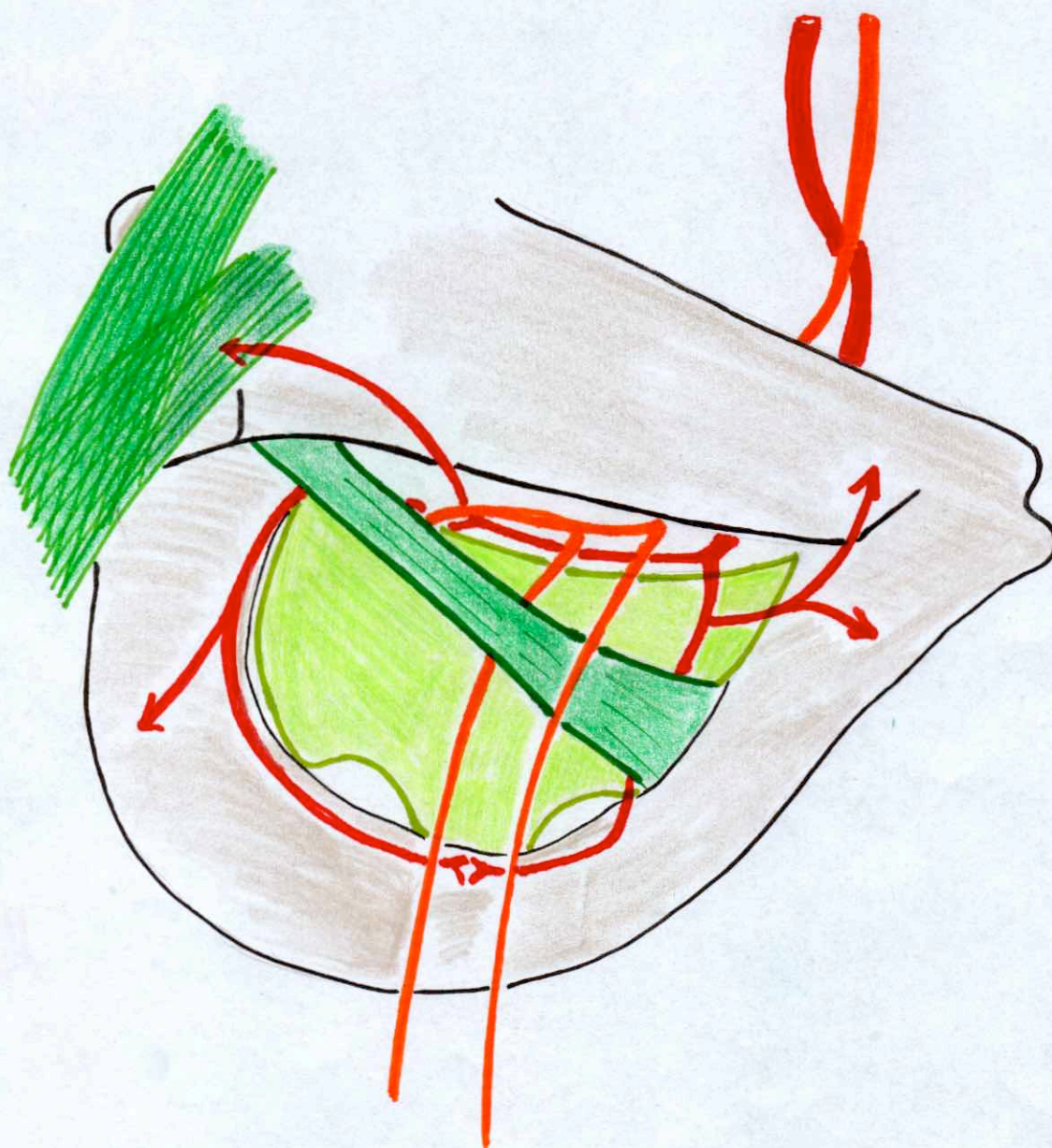


FACE EXOPELVIANNE - VASCULARISATION
- INNERVATION
FORAMEN OBTURÉ



CR
↑
MED →